


AJCC 7th Edition Staging
Disease Site Webinar
Lung

Donna M. Gress, RHIT, CTR



AJCC
American Joint Committee on Cancer
Validating science. Improving patient care.

The presentation was supported by the Cooperative Agreement Number DP13-1310 from The Centers for Disease Control and Prevention. Its contents are solely the responsibility of the authors and do not necessarily represent the official views of The Centers for Disease Control and Prevention.

This webinar is sponsored by

The Centers for Disease Control and Prevention

Supported by the Cooperative Agreement Number DP13-1310


The findings and conclusions in this report are those of the authors and do not necessarily represent the official position of the Centers for Disease Control and Prevention.

National Center for Chronic Disease Prevention and Health Promotion
National Program of Cancer Registries



Overview


- Highlights of disease site chapter
- Uniqueness, differences and exceptions based on
 - Anatomy
 - Diagnostic workup
 - Treatment
 - Outcomes
- Cautions and reminders for staging



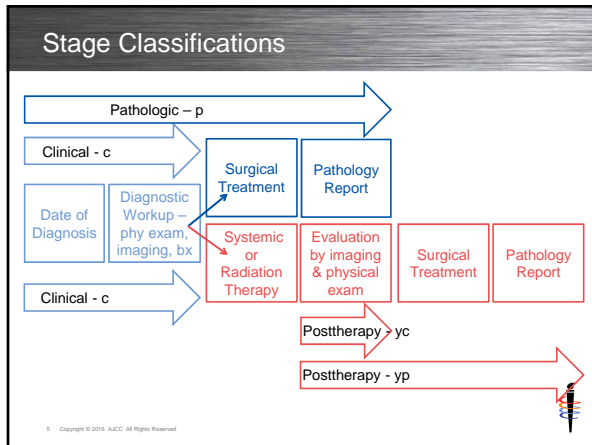
3 Copyright © 2018 AJCC. All Rights Reserved

Learning Objectives

- Recognize differences based on disease site
- Examine criteria for assigning stage
- Analyze effect of uniqueness on staging
- Employ critical thinking in using physician documentation
- Utilize appropriate guidelines to gain knowledge
- Identify resources for AJCC staging



4 Copyright © 2016 AJCC. All Rights Reserved

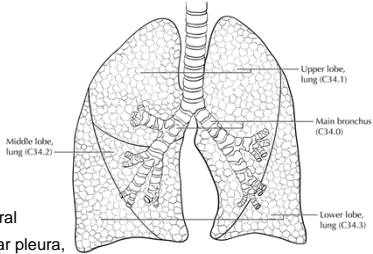


Anatomy Affecting Stage



Lung Anatomy

- Critical to understand lung anatomy for tumor location
 - Carina
 - Main bronchi
 - Lobar bronchi
 - Bronchioles
 - Lobe locations
 - Lobe fissures
 - Hilum
 - Mediastinum
 - Apex, medial, lateral
 - Pleural based: near pleura, in periphery of lung



Upper lobe, lung (C34.1)
Main bronchus (C34.0)
Lower lobe, lung (C34.3)
Middle lobe, lung (C34.2)

Compton, C.C., Byrd, D.R., et al., Editors. AJCC Cancer Staging Atlas, 2nd Edition. New York: Springer, 2012. ©American Joint Committee on Cancer

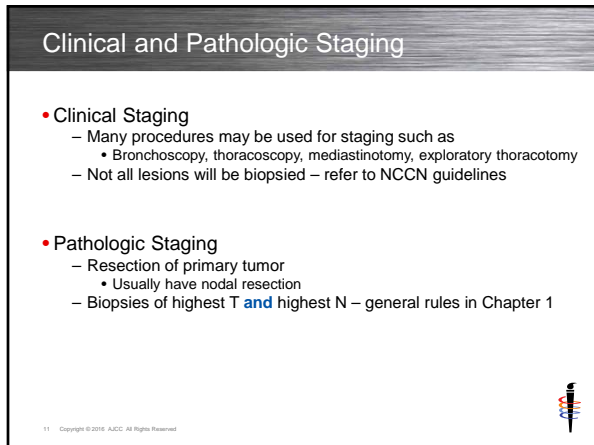
Lung Anatomy

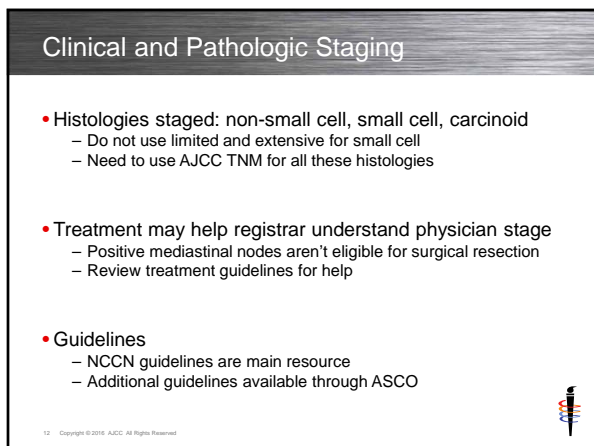
- Anatomy courses are critical
 - Improve skills by reviewing material
 - Many available through online courses
 - Invest in anatomy books
- Understanding diagnostic procedures plays role in staging
 - Knowing what can be visualized by
 - Endoscopy procedures: bronchoscopy, mediastinoscopy
 - Thoracotomies and mediastinotomies
 - Online information or books

Hilum and Mediastinum

- Anatomic definitions
 - Hilum is location where bronchi, blood vessels enter lung
 - Mediastinum contains heart, trachea, esophagus, great vessels
- Hilar or mediastinal may refer to nodes or anatomic area
- Examples from CAnswer Forum
 - Rt hilar mass FNA, patient had RLL lobectomy
 - Hilar mass must be nodes since RLL lung is not near hilum
 - Large cavitary mass RUL extends into rt hilum
 - Need further info whether extending into hilum or hilar nodes
 - RUL mass, mediastinal adenopathy, FNA subcarinal node is neg
 - Not anatomic area, mediastinal nodes are not involved
 - 6cm mediastinal mass involving pulmonary arteries, chest wall, ribs
 - Anatomic area of mediastinum, could include nodes








Assigning T, N, M, Stage Group



T Category


- Multiple tumors not always separate tumor nodules
- Separate tumor nodules
 - **Intrapulmonary spread** from primary lesion
 - Affects assignment of T category or M category
 - T3 separate tumor nodule in same lobe
 - T4 separate tumor nodules in different ipsilateral lobe
 - M1a separate tumor nodules in contralateral lobe
- Some histologies have multiple synchronous tumors
 - Assign T category by largest tumor size, use (m)
 - **Must** use (m) to indicate tumor burden
 - Does **NOT** affect T category
- More information available in AJCC 7th ed lung chapter



14 Copyright © 2016 AJCC. All Rights Reserved

T Category

- TX N0 M0 is occult carcinoma stage
 - TX must be microscopic findings without visible tumor
 - Sputum cells or bronchial washings
 - If TX is tumor cannot be assessed
 - Physician may use TX not assessed with N1-3 or M1
 - With N0 M0, there is no tumor found and it isn't a cancer case
 - Don't misinterpret registry lack of information as occult



15 Copyright © 2016 AJCC. All Rights Reserved

T Category

Primary Tumor (T)

TX Primary tumor cannot be assessed, or tumor proven by the presence of malignant cells in sputum or bronchial washings but not visualized by imaging or bronchoscopy

T0 No evidence of primary tumor

Tis Carcinoma in situ

T1 Tumor 3 cm or less in greatest dimension, surrounded by lung or visceral pleura, without bronchoscopic evidence of invasion more proximal than the lobar bronchus (i.e., not in the main bronchus)*

T1a Tumor 2 cm or less in greatest dimension

T1b Tumor more than 2 cm but 3 cm or less in greatest dimension

T2 Tumor more than 3 cm but 7 cm or less or tumor with any of the following features (T2 tumors with these features are classified T2a if 5 cm or less): Involves main bronchus, 2 cm or more distal to the carina; Invades visceral pleura (PL1 or PL2); Associated with atelectasis or obstructive pneumonitis that extends to the hilar region but does not involve the entire lung

T2a Tumor more than 3 cm but 5 cm or less in greatest dimension

T2b Tumor more than 5 cm but 7 cm or less in greatest dimension

T3 Tumor more than 7 cm or one that directly invades any of the following: parietal pleural (PL3) chest wall (including superior sulcus tumors), diaphragm, phrenic nerve, mediastinal pleura, parietal pericardium; or tumor in the main bronchus (less than 2 cm distal to the carina* but without involvement of the carina; or associated atelectasis or obstructive pneumonitis of the entire lung or separate tumor nodule(s) in the same lobe

T4 Tumor of any size that invades any of the following: mediastinum, heart, great vessels, trachea, recurrent laryngeal nerve, esophagus, vertebral body, carina, separate tumor nodule(s) in a different ipsilateral lobe

*The uncommon superficial spreading tumor of any size with its invasive component limited to the bronchial wall, which may extend proximally to the main bronchus, is also classified as T1a.

16 Copyright © 2016, AJCC. All Rights Reserved.

N Category

- Mass, adenopathy, enlargement **NOT** nodal involvement
 - Was true 30-40yrs ago for chest x-rays
 - Not sensitive, must be large mass to be seen
 - Not true for CT, PET, MRI
 - Imaging is very sensitive and rarely malignant
 - Most often inflammatory or reactive process
- Cannot use old rules and apply to modern medicine
 - Rules must change and keep pace with changes in medicine
 - Choose accurate information/staging over historic compatibility

17 Copyright © 2016, AJCC. All Rights Reserved.

N Category

- Imaging evaluation of nodes is critical
 - Size
 - SUV (standardized uptake value) on PET
- Use critical thinking with imaging reports
 - Radiologist comments and interpretation
 - Managing physician comments in progress notes
- Size and SUV
 - Cannot provide absolute criteria and cutpoints
 - Must take into consideration other statements
 - Example: large size may be due to inflammation


18 Copyright © 2016, AJCC. All Rights Reserved.

N Category

Regional Lymph Nodes (N)

- NX Regional lymph nodes cannot be assessed
- N0 No regional lymph node metastases
- N1 Metastasis in ipsilateral peribronchial and/or ipsilateral hilar lymph nodes and intrapulmonary nodes, including involvement by direct extension
- N2 Metastasis in ipsilateral mediastinal and/or subcarinal lymph node(s)
- N3 Metastasis in contralateral mediastinal, contralateral hilar, ipsilateral or contralateral scalene, or supraclavicular lymph node(s)


19 Copyright © 2016 AJCC. All Rights Reserved



M Category

- Important to assign subcategories
 - Even though stage group not affected
 - Critical to have M1a and M1b data
 - Data may lead to different stage groups in future
- 7th edition errata
 - Ensure errata added to chapter
 - M1b had additional clarifying information added


20 Copyright © 2016 AJCC. All Rights Reserved



Not M Category

- Chest wall invasion is T3, *not* M1b
- Chest wall includes
 - Ribs
 - Sternum
 - Skeletal muscle
 - Diaphragm

21 Copyright © 2016 AJCC. All Rights Reserved




M Category

Distant Metastasis (M)

M0	No distant metastasis
M1	Distant metastasis
M1a	Separate tumor nodule(s) in a contralateral lobe tumor with pleural nodules or malignant pleural (or pericardial) effusion*
M1b	Distant metastasis (in extrathoracic organs)

*Most pleural (and pericardial) effusions with lung cancer are due to tumor. In a few patients, however, multiple cytopathologic examinations of pleural (pericardial) fluid are negative for tumor, and the fluid is nonbloody and is not an exudate. Where these elements and clinical judgment dictate that the effusion is not related to the tumor, the effusion should be excluded as a staging element and the patient should be classified as M0.


22 Copyright © 2016 AJCC. All Rights Reserved.




AJCC Staging Rules

- Standard AJCC staging rules apply if no exceptions noted
- AJCC Curriculum for Registrars
 - Utilize this resource for staging rules
 - Slides available for download
 - Recordings available to watch at any time
- Refer to AJCC website for more information and education

23 Copyright © 2016 AJCC. All Rights Reserved.




Case Scenarios



Case #1 – Diagnostic Workup


- History/Chief Complaint
 - 58-year-old male with 2 week history of progressive cough, non-responsive to antibiotic treatment
- Physical Exam
 - Lungs: Wheezing on expiration
- Imaging
 - CXR: 1.7 cm nodule RUL, no adenopathy
- Procedure
 - Mediastinoscopy: no evidence of enlarged nodes
 - Biopsy right apical lung mass
- Pathology Report
 - Squamous cell carcinoma, biopsy right lung mass



25 Copyright © 2016 AJCC. All Rights Reserved

Case #1 – Clinical Staging


- Physical exam
 - No information that plays a role in staging
- Imaging
 - 1.7 cm nodule RUL
 - No adenopathy on CXR
 - But CXR is not sensitive and only shows extensive node involvement
- Procedure
 - Mediastinoscopy showed no nodal involvement
 - Biopsy does not play a role in assigning stage
- Pathology report
 - No information that plays a role in staging



26 Copyright © 2016 AJCC. All Rights Reserved

Case #1 – Clinical Staging Answer


- cT1a
 - Tumor \leq 2 cm surrounded by lung
- cN0
 - No nodal involvement on mediastinoscopy
 - No nodal involvement on imaging, but suspect since only CXR
- cM0
 - No signs or symptoms of mets
- Stage IA



27 Copyright © 2016 AJCC. All Rights Reserved

Case #1 – Treatment


- History/Chief Complaint
 - Admitted for surgery
- Operative Report
 - RUL lobectomy; Rt Apical mass; several enlarged hilar nodes
- Pathology Report
 - Right upper lobe lung: 5 cm, squamous cell ca, keratinizing type, mod differentiated. Visceral pleural invasion present. Focal extension into parietal pleura, presumed lymphovascular invasion. 4/9 nodes positive including 3/4 hilar nodes and 1 node at 4L paratracheal position. Margins neg.



28 Copyright © 2016 AJCC. All Rights Reserved

Case #1 – Pathologic Staging


- Surgery
 - Patient had surgical resection qualifying for pathologic staging
- Clinical staging information
 - cT1a cN0 cM0
- Operative report
 - Enlarged hilar nodes
- Pathology report
 - Size is 5 cm
 - Invasion of visceral and parietal pleura
 - Lymphovascular invasion doesn't play a role in staging
 - Hilar and 4L paratracheal nodes involved
 - Margins negative doesn't play a role in staging



29 Copyright © 2016 AJCC. All Rights Reserved

Case #1 – Pathologic Staging Answer

- pT3
 - 5 cm nodule RUL lung and visceral pleura invasion is T2a
 - Parietal pleura invasion is T3
- pN3
 - Ipsilateral hilar nodes is N1
 - Contralateral mediastinal nodes is N3
 - 4L lower paratracheal nodes is level 4 on the left
- cM0
 - No signs or symptoms of mets
- Stage IIIB




30 Copyright © 2016 AJCC. All Rights Reserved

Case #2 – Diagnostic Workup

- History/Chief Complaint
 - Lower back pain radiating into left hip
- Imaging
 - 4/19 MRI L Spine – numerous enhancing lesions, c/w extensive mets
 - 4/19 Hips – cortical loss left hemi-pelvis most likely neoplastic process
 - 4/23 Bone scan – mets in pelvis, multiple rib, and lumbar spine
- Procedures
 - 5/4 Fiberoptic bronchoscopy, bronchial washings RUL segments
 - 5/7 Image guided needle core biopsies of right lung medial mass
- Operative Findings
 - 5/4 RUL – no discrete mass, bronchial forceps bx anterior segment RUL
- Pathology
 - 5/4 Poorly differentiated carcinoma, cytology. Differential diagnosis primary ca of lung vs. metastasis from unknown primary
 - 5/7 Core biopsies with appearance suggestive of malignancy


31 Copyright © 2016 AJCC. All Rights Reserved.



Case #2 – Clinical Staging

- History/Chief Complaint
 - Pain which might be indicative of bone mets
- Imaging
 - Multiple extensive bone mets: pelvis, ribs, lumbar spine
 - Rib mets is not from direct extension to chest wall
 - No lung imaging
- Procedures and findings
 - RUL lung bronchus lesion
 - No discrete mass
- Pathology report
 - Carcinoma on bronchial washings cytology
 - Malignancy in RUL bronchus


32 Copyright © 2016 AJCC. All Rights Reserved.



Case #2 – Clinical Staging Answer

- cTX
 - No information on size or extent of lesion
- cNX
 - No information on involvement of nodes
- cM1b
 - Bone mets
- Stage IV


33 Copyright © 2016 AJCC. All Rights Reserved.



Case #2 – Treatment

- No treatment was provided
- Due to extensive disease, surgery is not appropriate


34 Copyright © 2016 AJCC. All Rights Reserved



Case #2 – Pathologic Staging

- No surgical treatment
- Patient does not qualify for pathologic staging


35 Copyright © 2016 AJCC. All Rights Reserved




Case #2 – Pathologic Staging Answer

- No T, N, M, or stage group may be assigned
- All categories left blank – does not qualify for staging
- Stage group may be coded as 99 for cancer registries

36 Copyright © 2016 AJCC. All Rights Reserved




Information and Questions
on AJCC Staging



AJCC Web site


- <https://cancerstaging.org>
- Cancer Staging Education **Registrar menu** includes
 - Timing is Everything – stage classification timeframe graphic
 - Presentations
 - Self-study or group lecture materials
 - Registrar's Guide to Chapter 1, AJCC Seventh Edition
 - Explaining Blanks and X, Ambiguous Terminology and Support for Staging
 - AJCC T, N, and M Category Options for Registry Data Items in 2016
 - AJCC Curriculum for Registrars
 - 4 free self-study modules of increasing difficulty on staging rules
 - Each module consists of 7 lessons, including recorded webinar with quizzes



38 Copyright © 2016 AJCC. All Rights Reserved.


AJCC Web site

- <https://cancerstaging.org>
- Cancer Staging Education **Physician menu** includes
 - Articles
 - 18 articles on AJCC staging in various medical journals
 - Webinars
 - 14 free webinars on staging rules and some disease sites
- Cancer Staging Education **General menu** includes
 - Staging Moments
 - 15 case-based presentations in cancer conference format to promote accurate staging with answers and rationales



39 Copyright © 2016 AJCC. All Rights Reserved.

AJCC Cancer Staging Manual and Atlas




Order at
<http://cancerstaging.net>

40 Copyright © 2016 AJCC. All Rights Reserved

CAnswer Forum

- Submit questions to AJCC Forum
 - Located within CAnswer Forum
 - Provides information for all
 - Allows tracking for educational purposes
- <http://cancerbulletin.facs.org/forums/>




41 Copyright © 2016 AJCC. All Rights Reserved

Summary



Summary

- Recognize differences based on disease site
 - Examine criteria for assigning stage
 - Effect of uniqueness of anatomy, workup, treatment
- Employ critical thinking in using physician documentation
 - Understanding current standard medical practice
 - Interpretation of available information
- Utilize guidelines available to registrars to gain knowledge
- Identify resources for AJCC staging
 - Information and guidance
 - Obtain answers to questions to learn staging
 - Understand rationale to apply to future cases
 - Not just an answer for today's case



43 Copyright © 2018 AJCC. All Rights Reserved.

Thank you

Donna M. Gress, RHIT, CTR
AJCC Technical Specialist



AJCC
American Joint Committee on Cancer
Validating science. Improving patient care.



633 N. Saint Clair, Chicago, IL 60611-3211
cancerstaging.org

No materials in this presentation may be repurposed without the express written permission of the American Joint Committee on Cancer. Permission requests may be submitted at CancerStaging.net

This webinar is sponsored by

The Centers for Disease Control and Prevention

Supported by the Cooperative Agreement Number DP13-1310

The findings and conclusions in this report are those of the authors and do not necessarily represent the official position of the Centers for Disease Control and Prevention.



National Center for Chronic Disease Prevention and Health Promotion
National Program of Cancer Registries
